

Which All-Ceramic System Is Optimal for Anterior Esthetics?

Frank Spear and Julie Holloway

J Am Dent Assoc 2008;139;19S-24S

The following resources related to this article are available online at jada.ada.org (this information is current as of April 17, 2011):

Updated information and services including high-resolution figures, can be found in the online version of this article at:

http://jada.ada.org/cgi/content/full/139/suppl_4/19S

Information about obtaining **reprints** of this article or about permission to reproduce this article in whole or in part can be found at:

<http://www.ada.org/prof/resources/pubs/jada/permissions.asp>

Which all-ceramic system is optimal for anterior esthetics?

Frank Spear, DDS, MSD; Julie Holloway, DDS, MS

Dentistry has undergone a revolution in the last 30 years, not only with regard to the introduction of new materials and techniques, but also with regard to the scientific evidence supporting their clinical applications. Land¹ introduced all-ceramic crowns in 1903, but the material was weak, the fabrication technique complicated and the choice of luting agents limited.

EVOLUTION OF ALL-CERAMIC MATERIALS

McLean² introduced alumina-reinforced porcelain jacket crowns in the mid-1960s. About 10 years later, research began to be published documenting the success—or lack thereof—of all-ceramic crowns.³ By the mid-1980s, the literature showed that anterior porcelain jacket crowns had a 25 percent chance of failing in vivo by 11 years; the failure rate was even higher in the posterior regions.⁴ Fortunately, significant advances in materials and techniques have occurred in the last 30 years that justify the routine use of all-ceramic

ABSTRACT

Background. As ceramic materials for dentistry evolve and patients' demand for esthetic restorations increases, practitioners must keep up with the science as well as the demand. The authors offer guidance to the practitioner in selecting the appropriate all-ceramic systems for crowns when faced with different esthetic demands.

Conclusions. Clinicians should reserve dental ceramics with high translucency for clinical applications in which high-level esthetics are required and the restoration can be bonded to tooth structure. Ceramics with high strength tend to be more opaque and pose a challenge when trying to match natural tooth color, but they can mask discoloration when present.

Practice Implications. Knowledge of the optical properties of available ceramic systems enable the clinician to make appropriate choices when faced with various esthetic challenges.

Key Words. All-ceramics; esthetics; crowns; veneers; restorative materials.

JADA 2008;139(9 suppl):19S-24S.

Dr. Spear is a founder and director, Seattle Institute for Advanced Dental Education, Seattle. Dr. Holloway is an associate professor and associate director of the advanced prosthodontics graduate education program, The Ohio State University College of Dentistry, 305 W. 12th Ave., Room 3005-U, Columbus, Ohio 43210, e-mail "holloway.3@osu.edu". Address reprint requests to Dr. Holloway.

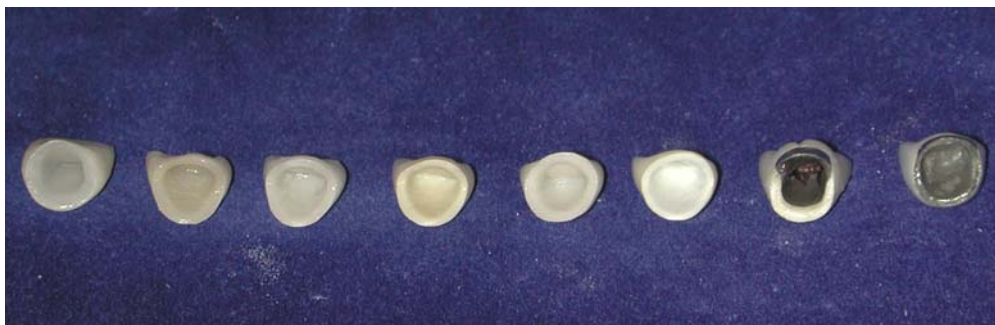

Figure 1. All-ceramic and metal-ceramic crowns. Translucent unlayered (left to right): Dicor (Dentsply, York, Pa.; no longer on the market), IPS Empress Esthetic (Ivoclar Vivadent, Amherst, N.Y.), OPC (Pen-tron Ceramics, Somerset, N.J.). Opaque layered: In-Ceram Alumina (Vita Zahnfabrik, Bad Säckingen, Germany), In-Ceram Spinel (Vita Zahnfabrik), Procera Zirconia (Nobel Biocare, Göteborg, Sweden). Metal-ceramic crown with porcelain labial margin and conventional metal-ceramic crown.

preparations with sub-gingival margins, these patients were faced with the potential risks of recession, exposure of the margin, discolored gingivae and pulpal involvement. These classic metal-ceramic restorations required not only extensive tooth reduction, but a highly skilled master technician to achieve excellent esthetics.

restorations in dentistry today.

One of the most significant of these changes occurred in 1983 when Horn⁵ and Simonsen and Calamia^{6,7} independently introduced acid-etched ceramics to create the bonded porcelain veneer, one of the most successful restorations when bonded primarily to enamel. With the advent of dentin adhesives in the early 1990s, porcelain restorations with significantly higher bond strengths than those that had been available previously became possible.^{8,9} This prompted many practitioners to forego metal-ceramics and use bonded ceramics in clinical situations in which they had never before been used—sometimes successfully and sometimes unsuccessfully. A challenge still exists in that the dentin/adhesive bond is not as durable or predictable as the enamel/adhesive bond.¹⁰

Major strides in technology permitting routine use of all-ceramic restorations are the improvement and scientific innovations in the ceramic materials themselves. High-strength core materials containing alumina, zirconia, zirconia-toughened alumina, magnesium aluminate spinel and lithium disilicate have been introduced and clinically tested. Laboratory technicians (ceramists) then apply esthetic veneering ceramics over these core materials to create a final, esthetic restoration.

The other change that has occurred in the use of all-ceramic restorations has been societal attitudes concerning esthetics. Before the early 1980s, people in the entertainment industry were primarily the only patients who requested elective esthetic dental procedures. With the only treatment option being full-mouth rehabilitation involving the use of complete-coverage crown

MATERIALS OPTIONS

Modern all-ceramic systems can be categorized broadly into two groups: those that are translucent and those that consist of an opaque, high-strength core onto which esthetic layering ceramic must be applied to achieve a natural appearance (Figure 1). Examples of translucent materials are conventional sintered feldspathic porcelain fabricated on refractory dies or platinum foil, pressable ceramics (for example, IPS Empress Esthetic, Ivoclar Vivadent, Amherst, N.Y.) and some of the in-office machinable ceramics made via computer-aided design/computer-aided manufacturing (for example, Vitablocs Mark II, Vita Zahnfabrik, Bad Säckingen, Germany). Examples of opaque layered materials are nonmetallic restorations made with alumina, zirconia or lithium disilicate used as high-strength core materials (for example, IPS e.max, Ivoclar Vivadent; Procera, Nobel Biocare, Göteborg, Sweden; In-Ceram, Vita Zahnfabrik; Lava, 3M ESPE, St. Paul, Minn.; and Cercon, Dentsply Ceramco, York, Pa.).

Properties. As a general rule, the two groups of all-ceramic systems have distinctly different properties in several areas. With regard to tooth reduction, clinicians can use the translucent materials with more conservative tooth preparations compared with the opaque, layered systems. Optically, the translucent materials usually are more esthetic than the layered materials. Most translucent restorations must be bonded to improve their predictability, while layered restorations do not have this sensitivity to choice of luting agent.¹¹

Because of these differences, dentists can use most opaque layered materials for traditional

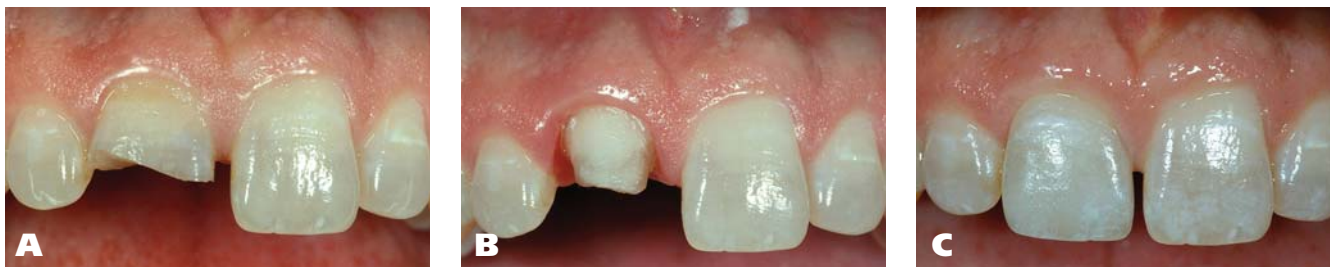

Figure 2. **A.** A central incisor fractured in an automobile accident without any pulpal involvement. **B.** The remaining tooth preparation is between 2 and 3 millimeters in height. **C.** The final restoration is a translucent unlayered (pressed ceramic) crown bonded to achieve acceptable retention.

crown or bridge restorations, while they can use translucent materials for full-coverage or more conservative partial-coverage bonded restorations. We can best summarize these differences as esthetic but weaker versus stronger but more opaque, a dichotomy that drives the process of selecting all-ceramic materials.¹²

Restorative needs. Dentists should base their choice of material on the requirements of the tooth being restored. For purposes of simplicity, we can group restorations into four major categories: porcelain laminate veneer restorations that replace primarily enamel, partial-coverage restorations that replace enamel and dentin, conventional complete crowns that cover acceptably colored dentin, and complete crowns that cover discolored dentin or metal posts that must be masked.

PARTIAL ENAMEL REPLACEMENT

The most conservative of all indirect restorations essentially replace enamel with minimal, if any, preparation into dentin. These restorations are useful when the overall tooth color is pleasing and the restorative goal is to place a new, more pleasing external surface on the tooth without changing the tooth color significantly.^{13,14} Because the enamel thickness of a natural tooth varies from 0.4 millimeters on the facial aspect in the cervical one-third to 0.8 to 1.0 mm on the facial aspect in the incisal one-third, true enamel replacement restorations typically are 0.3 to 0.5 mm thick and require minimal preparation.¹⁵ In general, some tooth preparation is desirable to allow for ideal cervical emergence contours.^{16,17} Because of the ceramic thickness needed for enamel replacement restorations, dentists should use only translucent unlayered materials.

In addition to the low possibility of pulpal irritation, margin placement is another advantage of enamel replacement restorations. The ultrathin,

highly translucent ceramic that makes changing color difficult with these restorations also allows them to have invisible supragingival margins.^{15,18} This allows conservative margin preparation short of the proximal contact or incisal edge and helps maintain gingival health.

DENTIN AND ENAMEL REPLACEMENT

As desirable as the conservative nature of enamel replacement restorations may be, many teeth simply cannot be treated minimally. Situations involving large interproximal restorations, tooth malposition, tooth discoloration, wear or fractures may require a restoration that involves the removal of more tooth structure but does not necessitate a conventional complete-coverage crown. When the clinician must replace both dentin and enamel but will not alter the occlusion or color, translucent ceramics still are the materials of choice, because of their excellent enamellike appearance and ability to be bonded to natural tooth structure.

COMPLETE CROWN AND ACCEPTABLY COLORED DENTIN

In general, the reasons to use an all-ceramic, complete-coverage crown for an anterior tooth include replacement of an existing crown; the tooth structurally requires that the lingual surface be prepared; the occlusion requires a significant change so that lingual coverage is needed; and large proximal areas of decay are present or the patient has pre-existing restorations. This is the one restoration for which clinicians may find it difficult to decide whether to use translucent materials or opaque, layered materials, because both may work equally well. In general, the decision will be based on the need for high strength owing to the lack of anterior guidance or the presence of parafunctional habits, the amount of tooth reduction required, the laboratory's preference

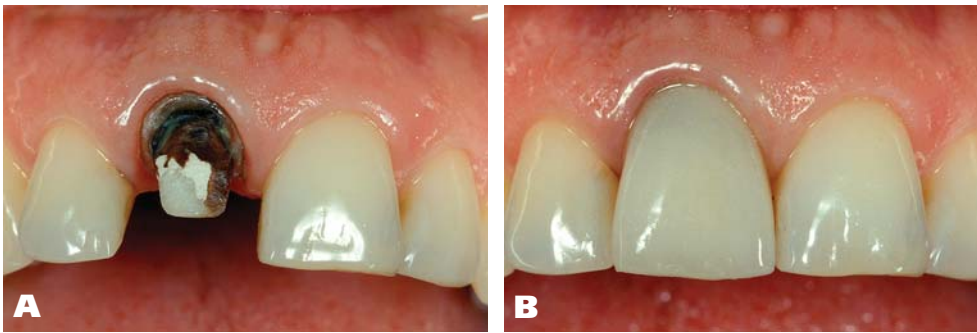


Figure 3. A. A discolored central incisor crown preparation. **B.** A translucent unlayered restoration at try-in. Note that even though the technician thought it had been opaqued adequately, the dark color of the tooth structure shows through.

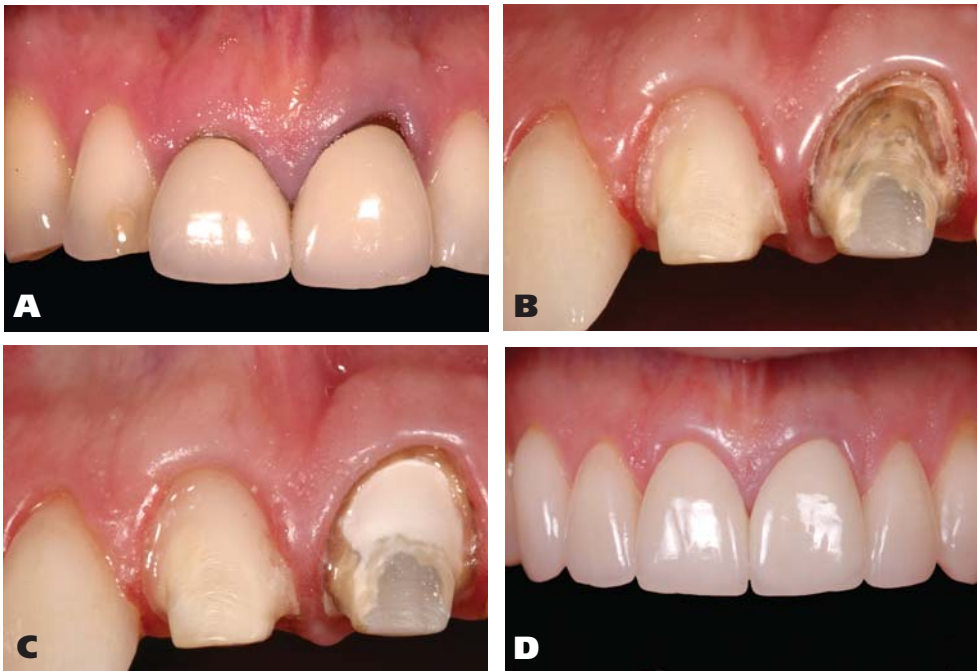

Figure 4. A. A patient needing veneer restorations to restore the worn lateral incisors and canines and crowns to replace the central incisor crowns. **B.** The cervical portion of the tooth preparation has been prepared an additional 0.3 millimeters to allow for opaque composite to be placed. **C.** Even though an opaque layered zirconia crown is used, opaquing the cervical portion prevents the dark preparation from showing through. **D.** The final restorations are sintered feldspathic veneers on teeth nos. 6, 7, 10 and 11 and layered zirconia-based crowns on teeth nos. 8 and 9.

and whether the clinician wishes to cement or adhesively bond the restoration.

For teeth with normally colored preparations, translucent materials enable clinicians to reduce less tooth structure (typically 1.0 mm), create esthetic margins when they are supragingival or equigingival, and achieve a predictable bond to the restoration itself, because sintered feldspathic ceramics and pressable ceramics are etched easily. This can be a particular advantage when an anterior tooth is fractured, because a tooth with a traditional cemented restoration might not have adequate resistance and retention form to

retain the restoration. This technique can be successful, but often it is the least predictable solution, because there is no way for the dentist to see the final color until the restoration is luted. This becomes difficult for the technician, who must estimate the impact that the tooth preparation color and cement will have on the final restoration color (Figure 3).

A far more predictable approach is to use a crown with a more opaque core that is less affected by the preparation color.^{25,26} The layered ceramic systems with more opaque cores are well-suited for the treatment of discolored teeth. The

By choosing an adhesively bonded, translucent ceramic, the dentist might be able to use as little as 2 mm of vertical preparation height without the need for additional foundation restorations^{19,20} (Figure 2).

COMPLETE CROWN AND DISCOLORED DENTIN OR METALLIC POST

A highly discolored anterior tooth presents an esthetic challenge. In such cases, the dentist will need to use a restorative technique capable of re-creating the natural color of dentin and then overlay the tooth preparation with a more translucent material to achieve an esthetic final appearance.

To achieve this, authors have advocated several approaches.²¹⁻²⁴ One method²¹ advocates that clinicians use relatively translucent ceramics, which have the greatest potential to be affected adversely by the color of the dark preparation, but also use an opaque cement to mask

technician can see the final restoration color during fabrication, because preparation color has little impact on the seated restoration. When using these restorations for discolored teeth, the clinician must ensure a reduction of 1.2 to 1.4 mm on the facial aspect, and he or she should use subgingival margins to avoid an unesthetic cervical appearance. Clinicians also should use these materials when the need arises to cover a metal post and core that cannot be removed²⁷ (Figure 4).

TABLE

Clinical situations.				
VARIABLE	PARTIAL COVERAGE ENAMEL REPLACEMENT ONLY	PARTIAL COVERAGE ENAMEL AND DENTIN REPLACEMENT	COMPLETE CROWN COVERING ACCEPTABLY COLORED DENTIN	COMPLETE CROWN COVERING DISCOLORED DENTIN OR METALLIC POST
Amount of Tooth Reduction	Minimal (0.3-0.5 mm*), in enamel only	As needed; does not involve lingual surface	Circumferential, 1.0-mm chamfer	Circumferential, 1.2- to 1.4-mm chamfer
Margin Placement	Supragingival	Supragingival or equigingival	Supragingival or equigingival	Subgingival
Strength Requirements	None, no occlusal forces encountered	Low, few occlusal forces encountered	Depends on presence of anterior guidance, parafunctional habits	Depends on presence of anterior guidance, parafunctional habits
All-Ceramic Material of Choice	Requires translucent ceramic	Requires translucent ceramic	Translucent or choose opaque ceramic if greater strength needed	Requires opaque ceramic
Cementation	Adhesive resin necessary	Adhesive resin necessary	Adhesive resin or conventional luting agent	Adhesive resin or conventional luting agent

* mm: Millimeters.

CONCLUSION

We have described the possible types of anterior restorations and the ceramic materials of choice for them. It is clear that the requirements for optical properties, tooth reduction, margin placement, strength and method of placement (bonded versus cemented) vary for different clinical situations. Is there a single material that can be used in all situations? The closest are the translucent systems, either sintered feldspathic or pressed ceramics, owing to their ability to be bonded to tooth structure, as well as to their translucency. How do dentists choose the material to use, particularly in the anterior region? First, we recommend that they take into consideration the laboratory's experience and expertise. Second, we advise them to refer to the table to best address the clinical situations encountered. ■

Disclosure. Drs. Spear and Holloway did not report any disclosures.

- Land CH. Porcelain dental art. *Dent Cosmos* 1903;65:615-620.
- McLean JW. The alumina reinforced porcelain jacket crown. *JADA* 1967;75(3):621-628.
- Jones DW, Wilson HJ. Some properties of dental ceramics. *J Oral Rehab* 1975;2(4):379-396.
- Leempoel PJ, Eschen S, De Haan AF, Van't Hof MA. An evaluation of crowns and bridges in general dental practice. *J Oral Rehabil* 1985;12(6):515-528.
- Horn HR. A new lamination: porcelain bonded to enamel. *N Y State Dent J* 1983;49(6):401-403.
- Simonsen RJ, Calamia JR. Tensile bond strengths of etched porcelain (abstract 1099). *J Dent Res* 1983;62.
- Calamia JR. Etched porcelain facial veneers: a new treatment

modality based on scientific and clinical evidence. *N Y J Dent* 1983;53(6):255-259.

8. Nakabayashi N, Nakamura M, Yasuda N. Hybrid layer as a dentin-bonding mechanism. *J Esthet Dent* 1991;3(4):133-138.

9. Pospiech P. All-ceramic crowns: bonding or cementing? *Clin Oral Investig* 2002;6(4):189-197.

10. Roberson TM, Heyman HO, Swift EJ Jr. *Sturdevant's Art and Science of Operative Dentistry*. 5th ed. St. Louis: Mosby; 2006:30-32.

11. Malamet KA, Socransky SS. Survival of Dicor glass-ceramic dental restorations over 16 years, part III: effect of luting agent and tooth or tooth-substitute core structure. *J Prosthet Dent* 2001;86(5):511-519.

12. Holloway JA, Miller RB. The effect of core translucency on the aesthetics of all-ceramic restorations. *Pract Periodontics Aesthet Dent* 1997;9(5):567-574.

13. Strassler HE. Minimally invasive porcelain veneers: indications for a conservative esthetic dentistry treatment modality. *Gen Dent* 2007;55(7):686-694.

14. Chu FC, Chow TW, Chai J. Contrast ratios and masking ability of three types of ceramic veneers. *J Prosthet Dent* 2007;98(5):359-364.

15. Ferrari M, Patroni S, Balleri P. Measurement of enamel thickness in relation to reduction for etched laminate veneers. *Int J Periodontics Restorative Dent* 1992;12(5):407-413.

16. Magne P, Belsler UC, Magne M. Ceramic laminate veneers: continuous evolution of indications. *J Esthet Dent* 1997;9(4):197-207.

17. Gurel G. *The Science and Art of Porcelain Laminate Veneers*. Chicago: Quintessence; 2003.

18. Garber DA. Porcelain laminate veneers: to prepare or not to prepare? *Compendium* 1991;12(3):178-182.

19. el-Mowafy OM, Fenton AH, Forrester N, Milenkovic M. Retention of metal ceramic crowns cemented with resin cements: effects of preparation taper and height. *J Prosthet Dent* 1996;76(5):524-529.

20. Browning WD, Nelson SK, Cibirka R, Myers ML. Comparison of luting cements for minimally retentive crown preparations. *Quintessence Int* 2002;33(2):95-100.

21. Okuda WH. Using a modified subopaquing technique to treat highly discolored dentition. *JADA* 2000;131(7):945-950.

22. Nixon RL. Masking severely tetracycline-stained teeth with ceramic laminate veneers. *Pract Periodontics Aesthet Dent* 1996;8(3):227-235.

23. Baratieri LN, Coral Neto AC, Monteiro Junior S, Caldeira de Andrada MA, Cardoso Vieira LC. The sandwich technique, an alternative treatment for tetracycline-stained teeth: a case report. *Quintessence Int* 2002;33(2):95-100.

sence Int 1991;22(12):929-933.

24. Barath VS, Faber FJ, Westland S, Niedermeier W. Spectrophotometric analysis of all-ceramic materials and their interaction with luting agents and different backgrounds. *Adv Dent Res* 2003;17:55-60.

25. Rasetto FH, Driscoll CF, Prestipino V, Masri R, von Fraunhofer JA. Light transmission through all-ceramic dental materials: a pilot study. *J Prosthet Dent* 2004;91(5):441-446.

26. Heffernan MJ, Aquilino SA, Diaz-Arnold AM, Haselton DR, Stanford CM, Vargas MA. Relative translucency of six all-ceramic systems, part II: core and veneer materials. *J Prosthet Dent* 2002;88(1):10-15.

27. Vichi A, Ferrari M, Davidson C. Influence of ceramic and cement thickness on the masking of various types of opaque posts. *J Prosthet Dent* 2000;83(4):412-417.